

Carlo Sorbara

**QUICK POCKET GUIDE
TO THE COMPREHENSIVE
TRANSESOPHAGEAL
ECHOCARDIOGRAPHIC EXAM**



SEEd

CONTENTS

Preface	4
General overview	5
GENERAL PRINCIPLES	7
Basic physics of ultrasound (US) equipment.....	8
Basic Doppler echocardiography	11
Terminology	19
Patient preparation.....	20
Procedure room equipment	22
Standard TEE probe positions.....	23
Standard TEE cross sections	24
STANDARD TEE CROSS SECTIONS: ANATOMIC CORRELATIONS	31
STANDARD BASIC TEE EXAM.....	53

CARDIAC MEASUREMENTS AND HEMODYNAMIC PARAMETERS: ABBREVIATIONS, DEFINITIONS, FORMULAS, AND REFERENCE LIMITS.....	77
REFERENCES & AUTHOR	103



PREFACE

The purpose of this guide is to provide quick and convenient access to a selection of different TRANS-ESOPHAGEAL ECHOCARDIOGRAPHY (TEE) cross sections, to show a comprehensive echocardiographic exam by the different TEE cross sections, with a list of the normal and abnormal echocardiographic cardiovascular measurements and hemodynamic parameters.

For each TEE view a probe position is given together with anatomic correlations and cardiac assessment.

The illustrated views are semi-schematic representations presented in their ideal shape.

The illustrations and examples were gathered from the patient files of:

- the Cardiovascular Anesthesia Unit of the Department of Anesthesiology at the University Hospital of Padova, Italy;
- the Cardiovascular Anesthesia and Intensive Care Department at the G.M. Lancisi Hospital of Ancona, Italy;
- the Cardiovascular Anesthesia and Intensive Care Department at the University Hospital "Careggi" of Florence, Italy.

All the echocardiographic and hemodynamic parameters are described as normal or abnormal by reference values [Lang et al, 2005; Zoghbi et al, 2003].

The quantification of the degree of abnormality with terms such as “mildly”, “moderately”, or “severely” abnormal (“red” reference values), as in the clinical practice, is the result of the application, in a different way for any parameter, of a combination of multiple statistical techniques, all of which have **significant limitations**.

The methods used to establish cut-off values of the different echocardiographic parameters are:

- the approach based on SD above or below the reference limit derived from a group of healthy people;
- the approach based on the definition of abnormality based on percentile values (e.g., 95th,99th) of measurements derived from a population that includes both healthy people and those with disease states;
- the approach based on the capability of a defined echocardiographic parameter to predict a mild or moderate or severe risk of a particular adverse outcome or prognosis;
- lastly, the approach based on determining the cut-off values from expert opinion, taking into account the collective experience of the References’ authors of having read and measured tens of thousands of echocardiograms.



GENERAL PRINCIPLES

BASIC PHYSICS OF ULTRASOUND (US) EQUIPMENT

The currently available TEE probes, a modification of a gastroscope probe, employ a transducer with the ability to alter the scanning **frequency** among 2.0, and 7.0 MHz, since the distance between the transducer and the cardiac structure is quite short and is not interrupted greatly by other body tissues. Velocity of ultrasound is a product of wavelength and frequency. Depth of tissue penetration is directly related to wavelength and inversely to frequency. Shorter wavelengths are associated with more scattering and attenuation. Increasing the imaging frequency improves resolution at the expense of tissue penetration. A lower frequency transducer, such as 3.5 MHz, has greater penetration (for structures farther away from the probe, such as the apical regions of the left ventricle) and in the Doppler examination is required to record high velocities since the measurable velocity. Depth of tissue penetration is directly related to wavelength and inversely to frequency. Shorter wavelengths are associated with more scattering and attenuation. Increasing the imaging frequency improves resolution at the expense of tissue penetration. A lower frequency transducer, such as 3.5 MHz, has greater penetration (for structures farther away from the probe, such as the apical regions of the left ventricle) and in the Doppler examination is required to record high velocities since the measurable velocities are inversely proportional to the

$$\frac{1}{\text{Wavelength}} \times \text{Frequency} \times \frac{1}{\text{Penetration}} \times \text{Resolution}$$

Ultrasound (US) frequency: > 20,000 cycles/second

transmitted frequency. Conversely the higher frequency transducer yields better resolution for detailed imaging and for structures closer to the probe, such as the aortic valve.

Decreasing the **depth** increases the pulse repetition frequency (PRF) (the number of times the piezoelectric crystal is electrically stimulated per second) and frame rate, thereby decreasing the time to scan an area of interest and increasing the number of lines that can be scanned. Field depth is important during spectral Doppler and color flow imaging examinations since the Nyquist limit (i.e., the maximum velocity to be recorded without aliasing) is related to the depth of the examination: the shallower the field depth, the higher the Nyquist limit. The depth is adjusted so that the structure being examined is centered in the display, and the focus is moved to the area of interest. In the adult set depth at 12 cm to compare between patients.

Increasing the **gain** increases the intensity of the generated ultrasound wave, the amplification of the received signal, and the brightness and noise of the image.

Compression determines the number of gray shades used to map the gray scale image on the display. Higher compression results in more shades of gray (a softer image); lower compression results in a more black and white image. Changing compression alters the range of returning ultrasound signals that will fall within the dynamic range of reflected echo signal intensities. Overall image gain (amplification of echoes) and dynamic range (compression) are adjusted so that the chambers are nearly black, but are distinct from the gray scales representing tissue.

Time (depth) gain compensation (TGC) are horizontal levers on the control that can be used to vertically adjust gain to compensate for temporal changes associated with variation of the ultrasound beam

penetration at increasing depths. Higher TGC levels result in higher levels of signal and noise at a given depth. TGC adjustment (gain adjusted by depth, i.e. time of echo) are set to create uniform brightness and contrast throughout the field.

Adjusting the **transmit focus** optimizes the focal zone of the transmitted signal to improve resolution in the near or far field.

Regional expansion selection (zoom) enables magnification and enhanced resolution of a selected 2D image viewed in real time.

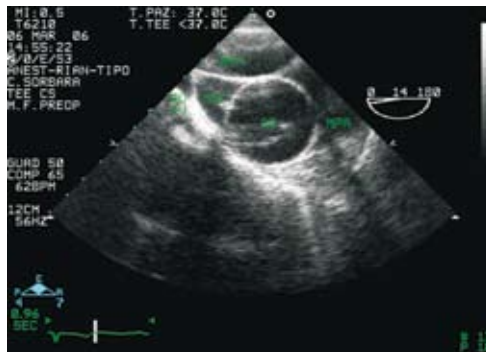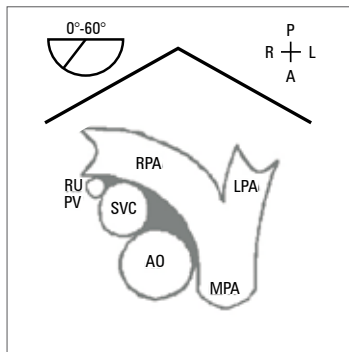
Processing adjusts the display of the relationship between grayscale pixel intensity and the ultrasound amplitude.

Edge varies the degree of sharpness of borders and edge enhancements within an image.

Adjusting the **persistence** changes the updating and averaging of consecutive frames on the screen to reduce noise and speckling.

**STANDARD
TEE CROSS SECTIONS:
ANATOMIC CORRELATIONS**

ME ASC AORTA SAX Midesophageal ascending aorta short axis view




Position: transducer tip at 25-30 cm from incisors, anteflexion, multiplane angle between 0 and 60 degrees.

Anatomy: great vessels, main pulmonary artery, right pulmonary artery, superior vena cava, ascending aorta (proximal and mid).

Assessment: main pulmonary artery PW Doppler analysis; diameter of the ascending aorta at the aortic valve annulus, at the sinotubular junction (STJ), and at specified distances from the STJ.

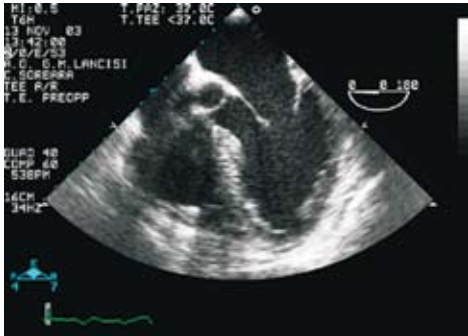


STANDARD BASIC TEE EXAM*



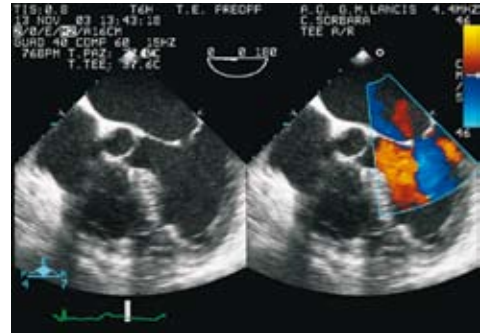
* personal sequence

ME four-chamber 14/16 cm 2D (0°-30°)



- LV morphology (area, diameters, thickness)
- Atrial septum bulging and PFO
- SWMA
- LV EDV
- LV ESV
- LV EF
- MV morphology
- LA diameter, area, volume

ME four-chamber 14/16 cm 2D/COLOR (0°-30°)



- Mitral valve morphology
- Mitral regurgitation
- TDI (Ea)
- Vp (color M-mode) for LAP
- IVRT (color M-mode)